

Adrenal collision tumor (parachordoma and ganglioneuroma): A case report

YULIN LAI^{1,2*}, LIANG ZHOU^{1,2*}, JIA HU¹, WENHUA LI¹, LIN CUI¹, YONGQING LAI^{1*} and LIANGCHAO NI^{1*}

¹Department of Urology, Peking University Shenzhen Hospital, Institute of Urology of Shenzhen PKU-HKUST Medical Center, Shenzhen, Guangdong 518036; ²Graduate Institute, Guangzhou Medical University, Guangzhou, Guangdong 511436, P.R. China

Received November 24, 2017; Accepted March 29, 2018

DOI: 10.3892/mco.2018.1610

Abstract. Adrenal collision tumors (ACTs) are distinct tumors that occur simultaneously in the same adrenal gland and are very rare. We herein report the case of a 56-year-old woman who was admitted to the hospital for medical imaging. The findings of the physical and laboratory examinations, including endocrine function, were unremarkable. Contrast-enhanced computed tomography of the abdomen revealed a 28x20x33-mm mass in the left adrenal medial limb, for which a laparoscopic surgery was performed. Postoperative pathological examination revealed two distinct tumors, namely a parachordoma and a ganglioneuroma. To the best of our knowledge, and following a thorough literature search, this is the first report of coexisting parachordoma and ganglioneuroma in the same adrenal gland.

Introduction

Adrenal collision tumors (ACTs) are uncommon masses consisting of two biologically distinct tumor types in the same adrenal gland (1-3). In general, collision tumors are difficult to diagnose by imaging studies, such as B-type ultrasonography, computed tomography (CT) (4) and magnetic resonance imaging (MRI) (5,6). Therefore, postoperative histopathological examination is considered the gold standard for the diagnosis of collision tumors. Ganglioneuromas, mostly originating from primordial neural crest cells, are rare benign tumors, while parachordomas are rare slow-growing tumors with low invasive potential, which mainly develop in the limbs, chest, abdomen and back (7). Furthermore, parachordoma as well as ganglioneuroma mainly appear as single

space-occupying lesions. Therefore, both tumors in the same adrenal gland is a rare occurrence and, thus far, there have been no published reports of parachordoma and ganglioneuroma as components of an ACT.

Case report

In April 2017, a 56-year-old woman was found to have a left adrenal space-occupying lesion on an MRI examination, without any associated discomfort. The MRI revealed a 25x19-mm nodular, irregular mass, appearing as a long T1 and long T2 signal shadow in the inferior margin of the left adrenal gland, with slight enhancement on contrast-enhanced imaging, which indicated a neurogenic tumor. This tumor was considered to originate from the adrenal gland (Fig. 1A). The patient was in good health and had no symptoms indicating hormonal imbalance. Moreover, there were no abnormalities on systematic review and physical examination. The laboratory examination revealed no major abnormalities in the blood cell counts, liver and kidney function tests, or serum electrolytes. The plasma adrenocorticotropic hormone level was 18.5, 36.8 and 19.5 pg/ml at 0, 8 and 16 h, respectively (normal range 0-20, 6.0-40 and 3.0-30 pg/ml, respectively), and the serum cortisol level was 0.80, 7.2 and 1.6 µg/dl at 0, 8 and 16 h, respectively (normal range 0-9.7, 3.7-19.4, 2.9-17.3 µg/dl, respectively). The B-ultrasound examination revealed a 24x16-mm solid and hypoechoic lesion without an obvious blood flow signal in the left adrenal gland. Furthermore, an adrenal CT scan revealed a space-occupying lesion (sized ~28x20x33 mm) in the inferior margin of the left adrenal gland (Fig. 1B), and the CT value of the plain scan only differed by 2 HU from that of arterial phase CT. Therefore, the possibility of a ganglioneuroma was first considered. After excluding surgical contraindications, laparoscopic surgery for adrenal tumor resection was successfully performed.

On gross examination, the lesion was composed of two masses with a fibrous capsule (Fig. 2A). Microscopically, the postoperative histological examination confirmed the mass as an ACT, consisting of a parachordoma coexisting with a ganglioneuroma. The larger mass was composed of fibrocartilaginous matrix and tumor cells arranged in a funicular or adenoid duct pattern, with pale red cytoplasm, without mitotic figures (Fig. 2B). The smaller mass was mainly composed of ganglion cells and spindle-shaped nerve

Correspondence to: Dr Liangchao Ni, Department of Urology, Peking University Shenzhen Hospital, Institute of Urology of Shenzhen PKU-HKUST Medical Center, 1120 Lianhua Road, Shenzhen 518036, P.R. China
E-mail: lncord@163.com

*Contributed equally

Key words: collision tumor, parachordoma, ganglioneuroma

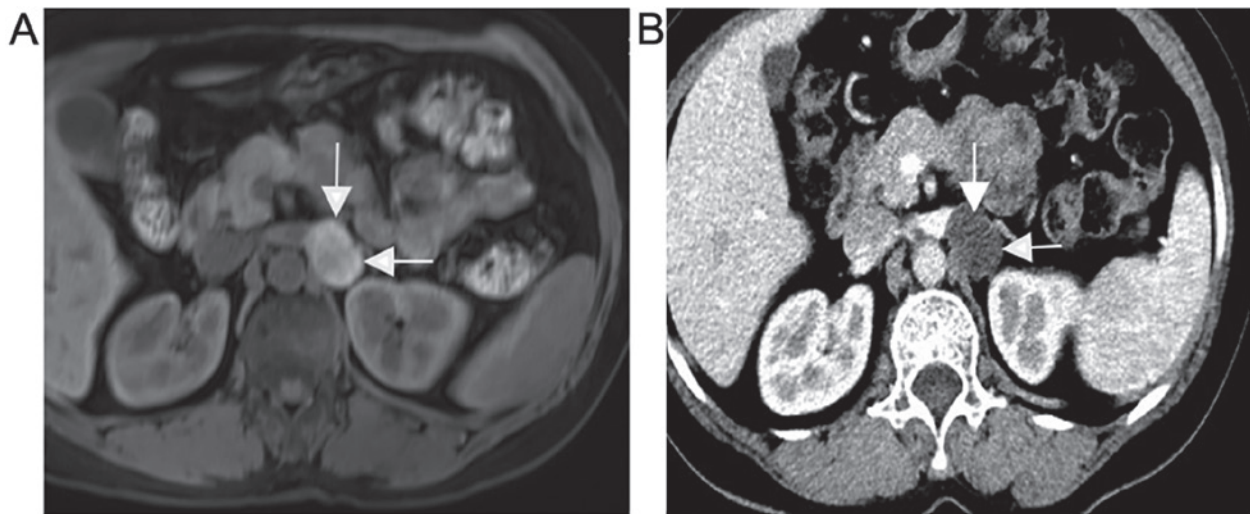


Figure 1. Imaging findings of the patient. (A) On T2 magnetic resonance imaging, the 25x19-mm mass (arrows) appeared as a nodular, irregular and long T2 signal shadow in the inferior margin of the left adrenal gland, slightly enhanced on contrast-enhanced imaging, suggesting a neurogenic tumor. (B) Enhanced computed tomography revealed a space-occupying lesion (sized ~28x20x33 mm) in the inferior margin of the left adrenal gland (arrows).

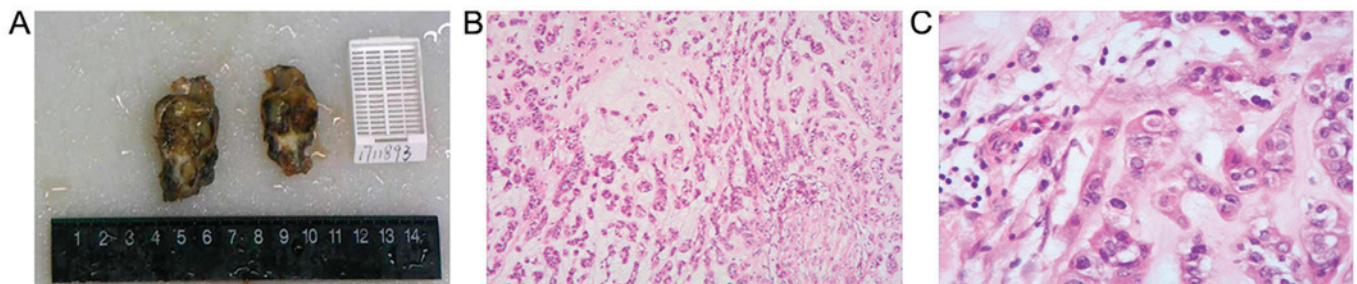


Figure 2. Histological findings of the patient. (A) Macroscopically, the lesion was composed of two masses with a fibrous capsule. (B) The tumor cells were arranged in a funicular or adenoid duct pattern with pale red cytoplasm, but without mitotic figures (hematoxylin and eosin staining; magnification, x100), consistent with the diagnosis of parachordoma. (C) The smaller tumor was mainly composed of ganglion cells and spindle-shaped nerve fibers, and the tumor cells exhibited no heteromorphism, findings consistent with the diagnosis of ganglioneuroma (hematoxylin and eosin staining; magnification, x400).

fibers, and the tumor cells did not exhibit any heteromorphism (Fig. 2C). Immunohistochemical staining revealed that S-100, cytokeratin, synaptophysin (Syn), calponin and chromogranin A (CgA) were positive in the parachordoma, whereas S-100, Syn, calponin and CgA were positive in the ganglioneuroma. The postoperative recovery was uneventful, and there were no abnormalities on the 3-month postoperative radiographic follow-up examination.

Discussion

ACTs are defined as two or more biologically distinct tumor types occurring simultaneously without admixture in the adrenal gland (8). Thus far, nearly 100 cases of ACTs have been reported (1); however, to the best of our knowledge, this is the first report of an ACT consisting of a parachordoma coexisting with a ganglioneuroma. However, the actual prevalence of ACTs remains unclear (2). Although some hypotheses have been suggested, the pathogenesis of ACTs is currently under investigation (2,4,9).

Parachordoma is a rare soft tissue tumor, and its origin remains unknown (10). Parachordoma was initially described

as ‘chordoma periphericum’ by Lawskowski in 1951 (11). According to reports in the literature, the clinical manifestations of parachordoma mainly include a painless mass of varying size and the imaging findings are non-specific. Thus, parachordoma is difficult to diagnose by preoperative imaging alone (7). According to the WHO International Classification of Diseases for Oncology, parachordoma is an intermediate tumor with local invasive potential (7). At present, the main treatment for parachordoma is surgical resection. Due to the possibility of local recurrence and metastasis after surgical resection (12), regular postoperative follow-up should be performed. Overall, the prognosis is good following surgical resection.

Similarly, the prevalence of adrenal ganglioneuroma is also unclear (9,13). Ganglioneuromas are infrequent benign tumors, which often manifest as a well-demarcated masses, and are composed of mature Schwann cells, nerve fibers and ganglion cells (14). Thus, they seldom develop local recurrence or distant metastasis (15).

In conclusion, parachordoma and ganglioneuroma are infrequent components of ACTs. Histopathological examination is the gold standard for diagnosis. Although parachordoma

and ganglioneuroma are usually benign, they have malignant transformation potential. Thus, a detailed evaluation of the patient to detect tumor spread is necessary, including laboratory, endocrine and imaging studies. After excluding surgical contraindications, surgical treatment is the preferred option for patients with a mass of ≥ 4 cm in size, or if there is a suspicion of malignant transformation, such as newly emerging hormonal symptoms or abnormal endocrine function results. Moreover, postoperative follow-up is crucial for detecting any local recurrence and distant metastasis at an early stage. In general, the prognosis of ACTs with coexisting benign tumors is good, and the focus should be placed on excluding the possibility of malignant transformation. Malignant tumors, such as kidney cancer and metastatic tumors, must also be included in the differential diagnosis. The coexistence of parachordoma and ganglioneuroma in the left adrenal gland as an ACT is unprecedented. Clinically, two different types of tumors, which coexist, may be encountered, which may complicate the diagnosis, and may even lead to misdiagnosis. Therefore, it is important to distinguish ACTs from other types of adrenal masses.

Acknowledgements

Not applicable.

Funding

The present study was supported by the National Natural Science Foundation of China (grant no.81101922), the Science and Technology Development Fund Project of Shenzhen (grant nos. JCYJ20150403091443329 and JCYJ20170307111334308), the fund of 'San-ming' Project of Medicine in Shenzhen and the fund of Guangdong Key Medical Subject.

Availability of data and materials

All data generated or analyzed during this study are included in this published article.

Authors' contributions

LN and YL conceived and designed the study. JH, WL and LC collected literature data and clinical information. YL and LZ drafted and edited the manuscript. All the authors have read and approved the final version of the manuscript.

Ethics approval and consent to participate

The patient provided written informed consent preoperatively.

Consent for publication

The reported case has been approved by the patient for academic exchange only.

Competing interests

The authors declare that they have no competing interests.

References

1. Lee HS, Choi YJ, Kim C and Kim BH: Adrenal collision tumor: coexistence of pigmented adrenal cortical oncocytoma and ganglioneuroma. *Case Rep Surg* 2016: 5790645, 2016.
2. Schwartz LH, Macari M, Huvos AG and Panicek DM: Collision tumors of the adrenal gland: Demonstration and characterization at MR imaging. *Radiology* 201: 757-760, 1996.
3. Sung CT, Shetty A, Menias CO, Houshyar R, Chatterjee S, Lee TK, Tung P, Helmy M and Lall C: Collision and composite tumors; radiologic and pathologic correlation. *Abdom Radiol (NY)* 42: 2909-2926, 2017.
4. Siddiqi AJ, Miller FH, Kasuganti D and Nikolaidis P: Adrenal hemangioma-adenoma: An exceedingly rare adrenal collision tumor. *J Magn Reson Imaging* 29: 949-952, 2009.
5. Herr K, Muglia VF, Koff WJ and Westphalen AC: Imaging of the adrenal gland lesions. *Radiol Bras* 47: 228-239, 2014.
6. Elsayes KM, Mukundan G, Narra VR, Lewis JS Jr, Shirkhoda A, Farooki A and Brown JJ: Adrenal masses: Mr imaging features with pathologic correlation. *Radiographics* 24 (Suppl 1): S73-S86, 2004.
7. Ghanta RK, Uppin MS, Koti K, Hui M, Uppin SG and Mukherjee KK: Primary intracranial Parachordoma: An unusual tumor in brain. *Surg Neurol Int* 5 (Suppl 14): S506-S511, 2014.
8. Untch BR, Shia J, Downey RJ, Carrasquillo JA, Panicek DM and Strong VE: Imaging and management of a small cell lung cancer metastasis/adrenal adenoma collision tumor: A case report and review of the literature. *World J Surg Oncol* 12: 45, 2014.
9. Katabathina VS, Flaherty E, Kaza R, Ojili V, Chintapalli KN and Prasad SR: Adrenal collision tumors and their mimics: Multimodality imaging findings. *Cancer Imaging* 13: 602-610, 2013.
10. Clabeaux J, Hojnowski L, Valente A and Damron TA: Case report: Parachordoma of soft tissues of the arm. *Clin Orthop Relat Res* 466: 1251-1256, 2008.
11. Dabska M: Parachordoma: A new clinicopathologic entity. *Cancer* 40: 1586-1592, 1977.
12. Samaka RM and Kandil MA: Huge pelvic parachordoma: Fine needle aspiration cytology and histological differential diagnosis. *Rare Tumors* 4: e53, 2012.
13. Qing Y, Bin X, Jian W, Li G, Linhui W, Bing L, Huiqing W and Yinghao S: Adrenal ganglioneuromas: A 10-year experience in a Chinese population. *Surgery* 147: 854-860, 2010.
14. Zhou Y, Liang Q, Ou WT, Li ZY and Liu QL: Laparoscopic resection of primary adrenal ganglioneuroma: A case report and review of the literature. *Oncol Lett* 9: 2167-2170, 2015.
15. Srinivasan R, Koliyadan KS, Krishnand G and Bhat SS: Retroperitoneal ganglioneuroma with lymphnode metastasis: A case report. *Indian J Pathol Microbiol* 50: 32-35, 2007.