

# Monitoring of recurrent and superior laryngeal nerve function using an Airwayscope™ during thyroid surgery

KEI IJICHI<sup>1</sup>, HIROSHI SASANO<sup>2</sup>, MEGUMI HARIMA<sup>2</sup> and SHINGO MURAKAMI<sup>1</sup>

Departments of <sup>1</sup>Otolaryngology-Head and Neck Surgery and <sup>2</sup>Anesthesiology and Medical Crisis Management, Nagoya City University Graduate School of Medical Sciences, Nagoya, Aichi 467-8601, Japan

Received March 17, 2017; Accepted June 28, 2017

DOI: 10.3892/mco.2017.1385

**Abstract.** In thyroid surgery, intraoperative identification and preservation of the recurrent laryngeal nerve (RLN) and superior laryngeal nerve external branch (SLNEB) are crucial. Several reports have proposed that electromyography (EMG) monitoring is an acceptable adjunct for identification and preservation of the RLN. However, a limited number of hospitals have access to an EMG monitoring system. Therefore, the development of another viable monitoring method is required. The aim of the present study was to design a new RLN and SLNEB monitoring method combining an Airwayscope™ (AWS) and a facial nerve stimulator. The facial nerve-stimulating electrode stimulates the RLN or SLNEB, so that the movement of the vocal cord may be observed with an AWS. This monitoring method was performed on 10 patients with a thyroid tumor. In all the cases, RLN and SLNEB were identified and vocal cord function was preserved. All the patients exhibited normal vocal cord function following surgery. Thus, the new RLN and SLNEB monitoring method using an AWS and a facial nerve stimulator is useful in thyroid surgery, and this method may be used as a reliable and available alternative to EMG monitoring to ensure the normal function of the vocal cord.

## Introduction

In thyroid surgery, damage to the recurrent laryngeal nerve (RLN) and superior laryngeal nerve external branch (SLNEB) is the most serious complication. Therefore, it is necessary to identify and preserve these nerves. The electromyography (EMG) monitoring system represented by Nerve Integrity Monitor (NIM) (Medtronic Xomed, Jacksonville, FL, USA)

is useful for RLN and SLNEB preservation in cases in which the tumor is large, or if there is tumor invasion into the adjacent tissue. Recently, RLN monitoring with an EMG has become widely applied (1-9). Intraoperative nerve monitoring is necessary for nerve function preservation. However, not all hospitals are equipped with an EMG monitoring system and, as a result, RLN and SLNEB monitoring is difficult. Therefore, an alternative monitoring method is required, and it was this need that drove us to design a novel RLN and SLNEB monitoring method. When RLN and SLNEB are stimulated with a facial nerve stimulator (FNS), movement of the vocal cord may be observed with an Airwayscope™ (AWS; Ricoh, Tokyo, Japan), more efficiently compared with the laryngeal fiberscope during surgery. The successful combination of these devices was employed as a complete alternative to EMG. In the present study, we were able to not only monitor and preserve the nerves, but also to confirm the absence of RLN injury following resection.

## Materials and methods

**Equipment.** AWS is a laryngoscope currently being used for difficult cases of endotracheal intubation under general anesthesia. A fiberscope is attached to the tip of the laryngoscope blade, from which an image is observed via a 2.5-inch monitor (Fig. 1). An FNS is commonly used in parotid surgery and neurosurgery. The nerve is electrically stimulated by the FNS probe during surgery (Figs. 2 and 3).

**Method.** In the present study, the method of RLN monitoring was designed using these devices in unison. The FNS electrode stimulates the RLN, and the resulting movement of the vocal cord is observed with the AWS transorally. This method enables effective monitoring of the RLN and SLNEB during thyroid surgery. The AWS monitor and the fiber may be easily detached from the AWS blade, thus allowing for only the blade to be kept for insertion into the larynx during the operation. Moreover, an AWS is equipped with an external connection terminal and all operation staff may observe the movement of the vocal cord from an external TV monitor. The FNS is used with an amplitude of 0.5-2.0 mA, and a stimulus duration of 0.5 sec.

The present study was approved by the Institutional Review Board of Nagoya City University and all the partici-

---

*Correspondence to:* Dr Kei Ijichi, Department of Otolaryngology-Head and Neck Surgery, Nagoya City University Graduate School of Medical Sciences, 1 Kawasumi, Mizuho-cho, Mizuho-ku, Nagoya, Aichi 467-8601, Japan  
E-mail: kei.ijichi@gmail.com

**Key words:** thyroid surgery, laryngeal nerve, recurrent nerve, Airwayscope™, nerve monitoring

Table I. Patient and surgical characteristics with nerve monitoring.

Age, years	Sex	Pathology	Operation	Operative time, min
41	Female	Benign	Lobectomy	174
55	Male	Malignant	Lobectomy + CND	338
66	Male	Malignant	Lobectomy + CND	140
72	Female	Benign	Lobectomy	111
36	Female	Benign	Lobectomy	147
40	Male	Benign	Lobectomy	233
60	Female	Malignant	Lobectomy + CND	178
64	Female	Malignant	Thyroidectomy + CND	291
67	Female	Malignant	Thyroidectomy + CND	430
57	Male	Benign	Lobectomy	169

CND, central neck dissection.

pants provided informed consent. All associated images are used with permission of the companies.

## Results

**Patients.** The present study was conducted on 10 patients admitted to Nagoya City University Hospital (Nagoya, Aichi) in 2012 with an initial diagnosis of a thyroid tumor, who were considered suitable to undergo surgery with AWS and FNS monitoring (Table I).

**Procedure and outcome.** At the nerve monitoring step, the surgeon delivered the electrical stimulus to the RLN and SLNEB in the patient's operative field. At the same time, the anesthesiologist inserted the AWS blade into the larynx and positioned the fiberscope to observe the area surrounding the vocal cord. All the surgical staff was able to observe the response of the vocal cord to electrical stimulus in all cases.

The view from the monitor revealed that the vocal cord moved transversely in response to RLN stimulation. In addition, with SLNEB stimulation, vocal cord expansion and contraction were observed. The vocal cord movement was recorded to a DVD or hard disk, so that it may be reviewed after the operation.

In all cases, the RLN was preserved and the normality of motor nerve function was confirmed during surgery. No RLN palsy occurred postoperatively.

When assessing the vocal cord movement, the time required to insert the AWS blade into the larynx was ~2-5 min, apart from 1 case, in which 10 min were required to obtain a sufficient view of the vocal cord movement, as the laryngeal space was relatively narrow. The results were sufficient to confirm the safety and validity of this new monitoring method.

## Discussion

In the present study, a new RLN and SLNEB monitoring procedure was designed, combining an AWS and an FNS during thyroid surgery. Intraoperative identification and functional monitoring of the RLN and SLNEB are crucial in thyroid surgery. Several reports have proposed that EMG monitoring



Figure 1. Airwayscope™ (Ricoh, Tokyo, Japan). (A) Frontal and (B) lateral view.

is an acceptable adjunct for identification and preservation of the RLN. Most surgeons opt for the EMG monitoring approach with a commercially prepared NIM EMG endotracheal tube (1-9). There are, however, other alternatives to EMG systems that are similar to an NIM (e.g., Lantern, Magstim Co. Ltd., Carmarthenshire, UK; and Nerveana, Neurovision Medical Products Inc., Ventura, CA, USA) However, the number of hospitals that are equipped with an NIM or similar EMG system is limited. In response, the present study used a combination of an AWS and an FNS to develop an effective alternative to RLN and SLNEB monitoring that differs from an EMG in how the vocal cord movement is observed.

As a functional monitoring method, our technique has limitations compared with an EMG, as caution is required for there is no warning sound of mechanical damage when the nerve is stimulated. Furthermore, unlike EMG, our method

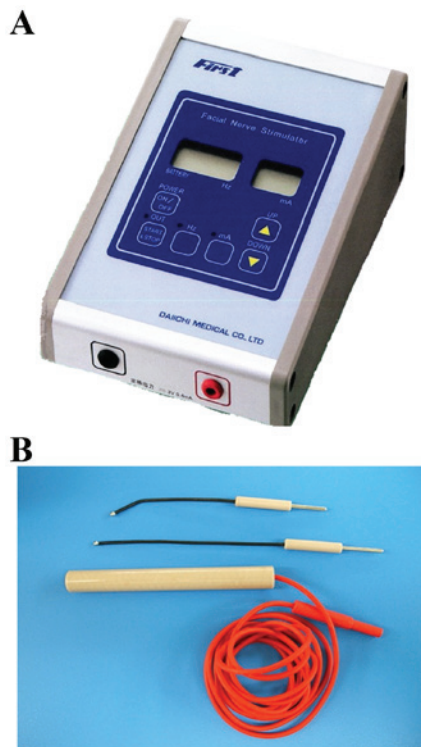


Figure 2. Facial nerve stimulator. (A) Main body and (B) stimulating electrode.

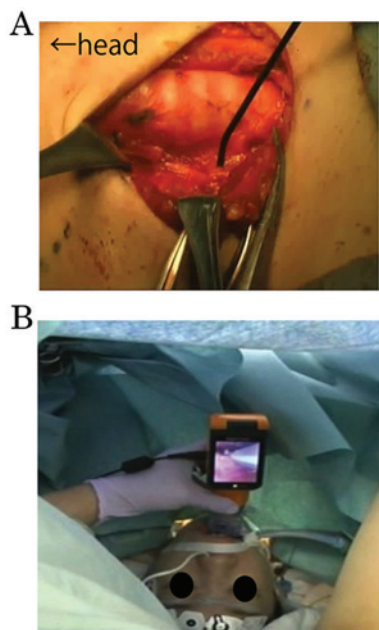


Figure 3. Setting up nerve monitoring. (A) Stimulation of the recurrent laryngeal nerve with the facial nerve stimulator. (B) Monitoring of vocal cord movement with Airwayscope™.

is unable to track electromyographic activity numerically. However, the primary goal of nerve monitoring is to evaluate neuro-functional status during surgery. In all 10 cases in this study, confirmation of the normality of vocal cord movement and the identification of the RLN were achieved. However, dysfunction of the NIM-EMG tube has been reported in

- a) Electric stimulation to the nerve
- ↓
- b) Acquire output signals for responses of muscle movement
- ↓
- c) Share the response signals among all staff in charge of the surgery

Figure 4. Steps of motor nerve monitoring.

3.8-23% of the cases (1). In our method, the setup failure is zero, as a sensing electrode is not used. In addition, vocal cord movement may be better observed with AWS rather than with a laryngeal fiberscope in the supine position. As regards the cost of the monitoring, a previous study reported that the use of an EMG tube for thyroid surgery increases the cost of each surgery, as the attached equipment is non-reusable and must be disposed of (8). Our method only requires an AWS blade and an FNS electrode, which is more cost-effective for each surgery when compared with an EMG tube and FNS electrode. In a previous report, the EMG response to stimulation of the vagus nerve was correlated with the postoperative functional status of the patients (10). With our method, at the end of surgery, patients exhibited a normal response to RLN stimulation and had no vocal cord palsy. In addition, no other complications were observed intra- or postoperatively.

The method described herein is a readily available alternative to an EMG when laryngeal nerve monitoring is unexpectedly required, such as in cases where a surgery suddenly reveals a non-recurrent laryngeal nerve. The AWS and FNS may be easily and quickly set up during surgery with the cooperation of the anesthesiologist.

Motor nerve monitoring consist of three steps: i) Electric stimulation of the nerve, ii) acquiring output signals for responses of muscle movement and iii) sharing the response signals among all surgical staff involved in the surgery (Fig. 4). This monitoring method has two benefits regarding the flow of medical information: First, the movie of the vocal cord movement may be exported to an external TV monitor connected to the AWS. The AWS may be connected by a plug into a jack on a side. All the surgical staff can share the information of laryngeal nerve function in real time. Second, this movie may be recorded onto a DVD or hard disk drive, so that laryngeal nerve preservation may be reconfirmed postoperatively. This method fulfills all the steps required for nerve monitoring as outlined above. Alternative laryngoscopes to an AWS include GlideScope (Verathon Inc., Bothell, WA, USA) and McGrath (Aircraft Medical Ltd., Edinburgh, UK), both of which are equipped with a monitor. However, at the time of this report, only an AWS was able to export the movie of the vocal cord movement to an external TV monitor.

Our method may allow assessment of neural integrity in parapharyngeal and cervical surgery, neurosurgery and thoracic surgery, with good approximation to the NIM system (11,12). However, in the case of neural tumor invasion or a large tumor around the nerve, nerve monitoring with an AWS and FNS is difficult.

In conclusion, the AWS and FNS method described herein is useful for conventional thyroid surgery, with an effectiveness similar to that of EMG monitoring.

Thus, the new RLN and SLNEB monitoring method using AWS and FNS is useful in thyroid surgery if only a confirmation of normal function of vocal cord is required. This method is more likely to be readily available and the results are similar to that of EMG monitoring, although there is no alert of mechanical damage to the nerve with this method. Moreover, this monitoring method also offers a more cost-effective alternative, with no loss of reliability, and it enables valuable sharing and reconfirmation of information on laryngeal nerve function during the surgery through the TV monitor.

## References

1. Lu IC, Chu KS, Tsai CJ, Wu CW, Kuo WR, Chen HY, Lee KW and Chiang FY: Optimal depth of NIM EMG endotracheal tube for intraoperative neuromonitoring of the recurrent laryngeal nerve during thyroidectomy. *World J Surg* 32: 1935-1939, 2008.
2. Donnellan KA, Pitman KT, Cannon CR, Replogle WH and Simmons JD: Intraoperative laryngeal nerve monitoring during thyroidectomy. *Arch Otolaryngol Head Neck Surg* 135: 1196-1198, 2009.
3. Julien N, Mosnier I, Bozorg Grayeli A, Nys P, Ferrary E and Sterkers O: Intraoperative laryngeal nerve monitoring during thyroidectomy and parathyroidectomy: A prospective study. *Eur Ann Otorhinolaryngol Head Neck Dis* 129: 69-76, 2012.
4. Chiang FY, Lee KW, Chen HC, Chen HY, Lu IC, Kuo WR, Hsieh MC and Wu CW: Standardization of intraoperative neuromonitoring of recurrent laryngeal nerve in thyroid operation. *World J Surg* 34: 223-229, 2010.
5. Tomoda C, Hirokawa Y, Uruno T, Takamura Y, Ito Y, Miya A, Kobayashi K, Matsuzuka F, Kuma K and Miyauchi A: Sensitivity and specificity of intraoperative recurrent laryngeal nerve stimulation test for predicting vocal cord palsy after thyroid surgery. *World J Surg* 30: 1230-1233, 2006.
6. Schneider R, Bures C, Lorenz K, Dralle H, Freissmuth M and Hermann M: Evolution of nerve injury with unexpected EMG signal recovery in thyroid surgery using continuous intraoperative neuromonitoring. *World J Surg* 37: 364-368, 2013.
7. Chiang FY, Lu IC, Kuo WR, Lee KW, Chang NC and Wu CW: The mechanism of recurrent laryngeal nerve injury during thyroid surgery-the application of intraoperative neuromonitoring. *Surgery* 143: 743-749, 2008.
8. Gremillion G, Fatakia A, Dornelles A and Amedee RG: Intraoperative recurrent laryngeal nerve monitoring in thyroid surgery: Is it worth the cost? *Ochsner J* 12: 363-366, 2012.
9. Mikuni N, Satow T, Taki J, Nishida N, Enatsu R and Hashimoto N: Endotracheal tube electrodes to map and monitor activities of the vagus nerve intraoperatively. Technical note. *J Neurosurg* 101: 536-540, 2004.
10. Morota N, Deletis V, Epstein FJ, Kofler M, Abbott R, Lee M and Ruskin K: Brain stem mapping: Neurophysiological localization of motor nuclei on the floor of the fourth ventricle. *Neurosurgery* 37: 922-930, 1995.
11. Zhao J, Xu H, Li W, Chen L, Zhong D and Zhou Y: Intraoperative recurrent laryngeal nerve monitoring during surgery for left lung cancer. *J Thorac Cardiovasc Surg* 140: 578-582, 2010.
12. Ito E, Ichikawa M, Itakura T, Ando H, Matsumoto Y, Oda K, Sato T, Watanabe T, Sakuma J and Saito K: Motor evoked potential monitoring of the vagus nerve with transcranial electrical stimulation during skull base surgeries. *J Neurosurg* 118: 195-201, 2013.