

Transanal minimally invasive surgery (TAMIS) with a GelPOINT® Path for lower rectal cancer as an alternative to transanal endoscopic microsurgery (TEM)

SHINGO NOURA^{1,2}, MASAYUKI OHUE¹, NORIKATSU MIYOSHI¹ and MASAYOSHI YASUI¹

¹Department of Surgery, Osaka Medical Center for Cancer and Cardiovascular Diseases, Osaka 537-8511; ²Department of Surgery, Osaka Rosai Hospital, Sakai, Osaka 591-8025, Japan

Received July 14, 2015; Accepted April 26, 2016

DOI: 10.3892/mco.2016.893

Abstract. Transanal endoscopic microsurgery (TEM) is a minimally invasive technique. However, TEM has not yet achieved widespread use. Recently, transanal minimally invasive surgery (TAMIS) using single-port surgery devices has been reported. In the present study, TAMIS using a GelPOINT® Path was performed in six patients with lower rectal cancer. A complete full-thickness excision was performed in all cases. The patient characteristics, operative techniques and operative outcomes were evaluated. The mean age of the patients was 63.0 years (range: 48-76). The mean operating time and blood loss were 86 min (range: 55-110) and 5 ml (range 0-10), respectively. There were no instances of morbidity or mortality. Additional transabdominal rectal resection was not performed, and adjuvant chemoradiotherapy was performed in all cases. The mean Wexner score was 0.6 (range: 0-3; n=5) at 6 months, and 0 (range: 0; n=4) at 12 months. TAMIS using a GelPOINT® Path was revealed to be easy and safe to perform. Although only a small number of cases were treated, the anal function following surgery was shown to be favorable, and the operation was demonstrated to be sufficiently feasible. Based on these results, TAMIS may, in time, assume a major role in the resection of large adenomas and early rectal cancers.

Introduction

The rectum is a challenging area for surgeons to operate on due to its limited access. Although advances in conventional surgery have broadened the choice of sphincter-preserving procedures, definitive colostomy is still necessary in 10-30% of patients (1). Furthermore, the postoperative morbidity and

mortality rates remain high (2). Besides urinary dysfunction, the disturbance of bowel function proves a major problem in ~30% of patients (3,4).

Benign neoplasia and early-stage rectal cancer located in the rectum have been traditionally managed with transanal excision (TAE) using a conventional instrument, such as a Parks retractor. This approach, however, has several limitations, as exposure and visibility within the rectal lumen curtail the surgeon's ability to perform a high-quality oncological excision. Since the introduction of transanal endoscopic microsurgery (TEM), which was first described by Buess *et al* (5), TEM has become the treatment of choice for benign lesions and early-stage cancers that are not suited to TAE using a conventional Parks retractor or flexible endoscope (6,7). TEM has also become a valuable option in selected patients with malignant rectal disease, in whom it may provide an acceptable oncological outcome with minimal postoperative morbidity and an improved functional outcome compared with standard radical resection (8,9). However, nearly 30 years after the introduction of TEM, this transanal platform has not achieved widespread adoption due to the cost and the complexity of the instruments, the steep learning curve and the requirement of specialized training to master the operation (10,11).

Although the instruments and procedures that are used in resection with TEM have remained largely unchanged since its introduction, there have been marked advances in technological innovation and technical expertise in the allied colorectal approaches. Considerable crossover potential now exists, whereby instrumentation designed for one application may be used for a different task (12). Transanal minimally invasive surgery (TAMIS) is a technique that was first developed for local excision of well-selected rectal neoplasia (13). Initially facilitated by existing single-port surgery devices, two platforms for transanal access, the GelPOINT® Path (Applied Medical, Rancho Santa Margarita, CA, USA) and the SILS™ Port (Covidien; now part of Medtronic, Mansfield, MA, USA) have recently gained the approval of the Food and Drug Administration for use in TAMIS. The GelPOINT® Path is the only platform to be specifically designed for TAMIS.

The present study describes the clinical application of TAMIS using a GelPOINT® Path, and the short-term results.

Correspondence to: Dr Shingo Noura, Department of Surgery, Osaka Rosai Hospital, 1179-3 Nagasone-cho, Kita-ku, Sakai, Osaka 591-8025, Japan
E-mail: s-noura@orh.go.jp

Key words: rectal cancer, transanal minimally invasive surgery (TAMIS), GelPOINT® Path

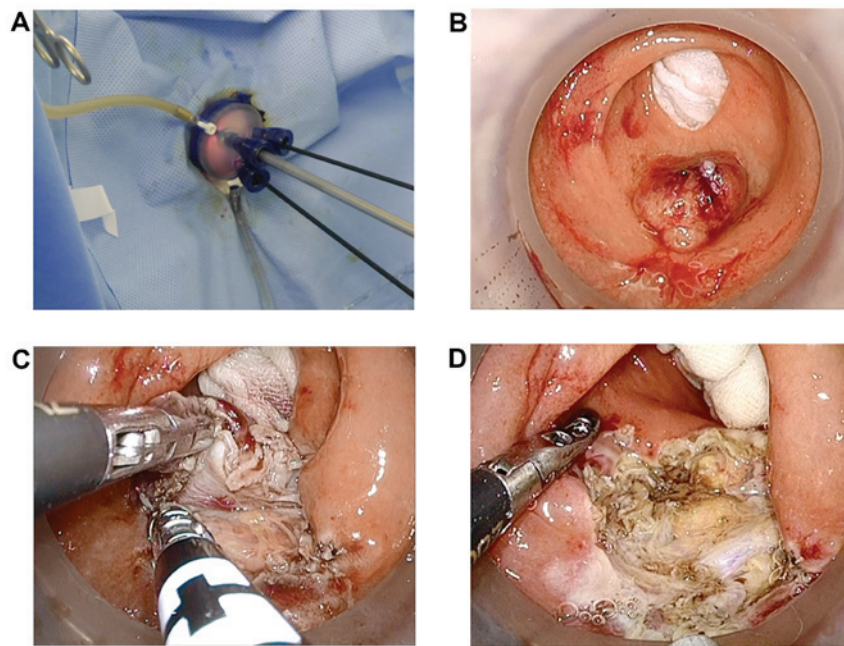


Figure 1. TAMIS (Transanal minimally invasive surgery) procedure. (A) The GelPOINT® Path is inserted through the anus. Three accessory ports are attached to the GelPOINT® Path, and the usual laparoscopic instruments are used. (B) A wet gauze is inserted in the oral side of the tumor to prevent the spread of CO₂ along the colon. (C) An endoscopic grasper and vessel-sealing device are used to facilitate a full-thickness excision. (D) The rectal wall defect is left open, and is not closed.

Patients and methods

Patients. Between December 2013 and March 2015, at the Department of Surgery in the Osaka Medical Center for Cancer and Cardiovascular Diseases (Osaka, Japan), TAMIS was performed using a GelPOINT® Path in six patients with lower rectal cancer, who were preoperatively diagnosed with clinically T1 or T2 lesions and no lymph node or distant metastasis. The patients did not receive preoperative chemotherapy or radiotherapy. To confirm the presence or absence of distant metastases prior to surgery, the cancer was staged in all patients with abdominal plus pelvic computed tomography (CT) and chest CT (using an Aquilion Prime TSX-303A scanner; Toshiba Medical Systems Corp., Tokyo, Japan). This study was approved by the Human Ethics Review Committee of Osaka Medical Center for Cancer and Cardiovascular Diseases and written informed consent was obtained from each patient.

Operative procedures. In our hospital, the use of TAMIS using a GelPOINT® Path is indicated by the presence of large adenomas or early rectal cancers. In the case of rectal cancer, the criteria to be met are a maximum diameter of ≤ 3 cm, clinically T1 or T2 depth, and the absence of lymph node and distant metastasis. Mechanical bowel preparation (using 2 l of a polyethylene glycol solution) was performed preoperatively, in an identical manner as in usual, conventional colorectal surgery, and intravenous antibiotics were administered perioperatively in all cases. Under general anesthesia, the patient was positioned according to the location of the rectal tumor, so that it could be endoscopically visualized in the six o'clock position for optimal excision. The surgeon was located between the patient's legs, while the camera assistant was situated to the right of the

surgeon. A GelPOINT® Path was inserted through the anus. Three accessory ports were attached to the GelPOINT® Path, and the usual laparoscopic instruments were used (Fig. 1A). Rectal CO₂ insufflation was established, and a smoke evacuator was applied to the other side of the device. Excellent views were obtained with a high-definition, flexible-tip laparoscope following the adequate expansion of the rectum by CO₂ insufflation, with an intrarectal pressure of 10 mm Hg and a flow of 10 l/min. A wet gauze was inserted in the oral side of the tumor to prevent the spread of CO₂ along the colon (Fig. 1B). The area to be excised was marked circumferentially with an electric cautery. An endoscopic grasper and vessel-sealing device were used to facilitate a full-thickness excision (Fig. 1C). After the complete removal of the lesion, the area was irrigated and checked for bleeding. Irrigation was performed with 1,000 ml of saline solution to prevent local recurrence. In all cases, the rectal wall defect was left open, and was not closed (Fig. 1D). To prevent postoperative bleeding, the gauze was filled. The gauze was removed on postoperative day (POD) 1.

Results

The patients' characteristics are summarized in Table I. The mean age of the patients was 63.0 years (range: 48-76). The mean tumor distance from the anal verge was 4.3 cm (range: 3.0-6.0). En bloc resection was possible, and the resection margin was negative in all cases. All the cases were histopathologically diagnosed with adenocarcinoma. The depth of tumor invasion was as follows: T1 (n=5) and T2 (n=1). The operative and clinical results are summarized in Table II. The mean operating time was 86 min (range: 55-110). The mean volume of blood loss was only 5 ml (range: 0-10). Essentially, patients drank water on POD 1 and ate a meal on

Table I. Patient characteristics.

Patient no.	Age/gender	Tumor location from anal verge (cm)	Maximum diameter (cm)	Resection margin	Final pathology
1	62/F	4.0	2.7	Negative	pT2, mod, ly(-), v(+)
2	64/M	3.0	3.0	Negative	pT1 (4,000 μ m), well, ly(-), v(+)
3	68/F	3.0	2.0	Negative	pT1 (4,000 μ m), well, ly(-), v(-)
4	48/M	4.0	3.0	Negative	pT1 (4,000 μ m), well, ly(-), v(-)
5	76/F	6.0	1.5	Negative	pT1 (2,500 μ m), mod, ly(-), v(+)
6	60/M	6.0	2.3	Negative	pT1 (4,500 μ m), mod, ly(-), v(+)

The depth of T1 invasion is indicated (as x μ m); well, well-differentiated adenocarcinoma; mod, moderately differentiated adenocarcinoma; ly, lymphatic invasion; v, venous invasion; F, female; M, male.

Table II. Operative and clinical results.

No.	Operative time (min)	Blood loss (ml)	Hospital stay (days)	Morbidity and mortality	Adjuvant therapy
1	69	5	7	None	CRT
2	110	5	7	None	CRT
3	55	0	7	None	CRT
4	90	5	6	None	CRT
5	110	10	7	None	CRT
6	86	5	8	None	CRT

CRT, chemoradiotherapy.

POD 2. The urinary catheter was removed on POD 1. The mean postoperative hospital stay was 7 days (range: 6-8). There were no instances of morbidity or mortality.

According to the Japanese Society for Cancer of the Colon and Rectum (JSCCR) guidelines (14), transabdominal intestinal resection with lymph node dissection was preferable or necessary in all the patients in the present study. However, after having obtained informed consent, adjuvant chemoradiotherapy (CRT) was administered without additional transabdominal resection. An S-1 (Taiho Pharmaceutical Co., Ltd., Tokyo, Japan) was administered with concurrent conventionally fractionated radiotherapy. S-1 (80 mg/m²) was administered orally twice daily, 5 days a week for 5 weeks. Radiotherapy was delivered using a three- or four-field technique 5 days a week at 1.8 Gy/day for 5 weeks, for a total dose of 45 Gy.

With regard to anorectal function following TAMIS, fecal incontinence was assessed by the Wexner score at 3, 6, 9 and 12 months following surgery. The mean Wexner score was 1.0 (range: 0-3, n=6) at 3 months, 0.6 (range: 0-3, n=5) at 6 months, 0 (range: 0, n=4) at 9 months, and 0 (range: 0, n=4) at 12 months.

Discussion

The approach to local excision rectal neoplasia was radically evolved in 1826 by Jacques Lisfranc (15). Subsequently,

operative techniques, such as the Parks excision (16), have progressed. Since its introduction into clinical practice (5), TEM has progressively become the standard for treatment of benign polyps and early neoplasms in TAE (6,7). Currently, the excision of rectal tumors by TEM is associated with fewer surgery-associated morbidities, an improved postoperative anorectal function and a shortened postoperative recovery when compared with open or laparoscopic rectal resections (8,9). Frail elderly patients, patients who are otherwise not suitable candidates for a major rectal resection, and patients who categorically refuse to undergo a radical rectal excision with permanent stoma creation for early-stage rectal cancer, are candidates for TAE (17). The widespread uptake of TEM, however, has been slow, in part due to the surgeon being forced to work through a long rigid rectoscope, which limits triangulation and the subsequent manipulation of the instruments.

To overcome these restrictions, using single-port access systems and the usual laparoscopic instruments, transanal endoscopic resection has recently become more accessible to general surgeons. TAMIS, which was a novel approach, was first reported by Atallah *et al* in 2010 (13). This was followed by various reports of the use of TAMIS in an increasing number of cases, using similar platforms with acceptable outcomes (18-21). TAMIS using a GelPOINT® Path provides excellent exposure of the operative field, due to its high-definition flexible tip camera and constant gas dilatation,

which allow for a more precise dissection. According to the depth of tumor, in the present study a full-thickness excision with clear margins was able to be performed. TAMIS using a single access port with standard laparoscopic instruments is an approach that should become much more accessible to a great number of surgeons. This is particularly important for general surgeons, as TEM is not part of standard general surgery. Thus, TAMIS may conveniently be utilized by general surgeons who have laparoscopic experience and an interest in transanal surgery. It also has the potential to further reduce the cost of TAMIS, since it is performed with a conventional laparoscopic video system, which is widely available in most institutions. Recently, a meta-analysis was performed of TEM vs. the standard TAE procedure (22). No difference was found between the techniques in the postoperative complication rate. However, TEM was associated with a higher rate of negative microscopic margin (odds ratio, 5.281; $P < 0.001$), a reduced rate of specimen fragmentation (odds ratio, 0.096; $P < 0.001$), and local recurrence (odds ratio, 0.248; $P < 0.001$). To perform TAMIS, the most critical issue is suturing (23). Ramirez *et al* (24) reported that it made no difference whether the defect was sutured or not, in terms of the intraoperative results and outcome. At 4 weeks post-surgery, the rectal wound was completely sealed in 84% of those patients whose wounds were not sutured. By contrast, the rectal wound was completely sealed in 95% of the patients whose wounds were sutured. Even if the defect was left open, continence was not compromised at one year following the surgery (25). These results suggest that it may be advantageous for the defect to be left open.

The major advantage of TEM is that it is associated with significantly lower morbidity and mortality in comparison with traditional treatments for malignant lesions, including abdominoperineal resection and low anterior resection (26). Postoperative complications are rare following TEM, and include postoperative bleeding (1.7-2.7%) and pelvic sepsis due to perforation (1-2.7%). The mortality associated with TEM is low (0-2%) (27). Surgical emphysema following TEM is a very rare complication (28). With the increasing use of TEM, including TAMIS, in the excision of rectal lesions, this complication should be noted.

TAMIS also has a great advantage over usual open or laparoscopic surgery with regard to anorectal function following surgery. If abdominoperineal resection is performed, permanent colostomy is necessary. Even when low anterior resection or intersphincteric resection preserving the anus are performed, patients experience frequent defecation or fecal incontinence. The Wexner score at one year following surgery of 4.4-10.0 points, as previously reported (29,30), is rather poor. By contrast, in the present study the Wexner score of 0 points at 12 months post-surgery was very good.

In conclusion, TAMIS using a GelPOINT® Path is a technique that is easy and safe to perform. Although the present study only included a small number of cases, the results regarding anorectal function were shown to be favorable and sufficiently feasible. However, further experience and clinical trials are required to evaluate the technical usefulness, oncological outcome, and the indications of this procedure. In the future, TAMIS may assume an important role in the resection of large adenomas and early rectal cancers.

Acknowledgements

The present study was supported in part by a Public Trust Surgery Research Fund.

References

- Morris E, Quirke P, Thomas JD, Fairley L, Cottier B and Forman D: Unacceptable variation in abdominoperineal excision rates for rectal cancer: Time to intervene? *Gut* 57: 1690-1697, 2008.
- Morino M, Parini U, Giraudo G, Salvai M, Brachet Contul R and Garrone C: Laparoscopic total mesorectal excision: A consecutive series of 100 patients. *Ann Surg* 237: 335-342, 2003.
- Ho P, Law WL, Chan SC, Lam CK and Chu KW: Functional outcome following low anterior resection with total mesorectal excision in the elderly. *Int J Colorectal Dis* 18: 230-233, 2003.
- Wallner C, Lange MM, Bonsing BA, Maas CP, Wallace CN, Dabhoiwala NF, Rutten HJ, Lamers WH, Deruiter MC and van de Velde CJ; Cooperative Clinical Investigators of the Dutch Total Mesorectal Excision Trial: Causes of fecal and urinary incontinence after total mesorectal excision for rectal cancer based on cadaveric surgery: A study from the Cooperative Clinical Investigators of the Dutch total mesorectal excision trial. *J Clin Oncol* 26: 4466-4472, 2008.
- Buess G, Theiss R, Günther M, Hutterer F and Pichlmaier H: Endoscopic surgery in the rectum. *Endoscopy* 17: 31-35, 1985.
- Moore JS, Cataldo PA, Osler T and Hyman NH: Transanal endoscopic microsurgery is more effective than traditional transanal excision for resection of rectal masses. *Dis Colon Rectum* 51: 1026-1030; discussion 1030-1021, 2008.
- Casadesus D: Surgical resection of rectal adenoma: A rapid review. *World J Gastroenterol* 15: 3851-3854, 2009.
- Bach SP, Hill J, Monson JR, Simson JN, Lane L, Merrie A, Warren B and Mortensen NJ; Association of Coloproctology of Great Britain and Ireland Transanal Endoscopic Microsurgery (TEM) Collaboration: A predictive model for local recurrence after transanal endoscopic microsurgery for rectal cancer. *Br J Surg* 96: 280-290, 2009.
- Doornbosch PG, Tollenaar RA, Gosselink MP, Stassen LP, Dijkhuis CM, Schouten WR, van de Velde CJ and de Graaf EJ: Quality of life after transanal endoscopic microsurgery and total mesorectal excision in early rectal cancer. *Colorectal Dis* 9: 553-558, 2007.
- Maslekar S, Pillinger SH, Sharma A, Taylor A and Monson JR: Cost analysis of transanal endoscopic microsurgery for rectal tumours. *Colorectal Dis* 9: 229-234, 2007.
- Koebbrugge B, Bosscha K and Ernst MF: Transanal endoscopic microsurgery for local excision of rectal lesions: Is there a learning curve? *Dig Surg* 26: 372-377, 2009.
- Cahill RA, Hompes R, Cunningham C and Mortensen NJ: Sealed orifice laparoscopic or endoscopic (SOLE) surgery: Technology and technique convergence for next-step colorectal surgery. *Colorectal Dis* 13 (Suppl 7): 3-7, 2011.
- Atallah S, Albert M and Larach S: Transanal minimally invasive surgery: A giant leap forward. *Surg Endosc* 24: 2200-2205, 2010.
- Watanabe T, Itabashi M, Shimada Y, Tanaka S, Ito Y, Ajioka Y, Hamaguchi T, Hyodo I, Igarashi M, Ishida H, *et al*: Japanese society for cancer of the colon and rectum (JSCCR) guidelines 2010 for the treatment of colorectal cancer. *Int J Clin Oncol* 17: 1-29, 2012.
- Lisfranc J: Classic articles in colonic and rectal surgery. Jacques Lisfranc 1790-1847. Observation on a cancerous condition of the rectum treated by excision. *Dis Colon Rectum* 26: 694-695, 1983.
- Parks AG: A technique for excising extensive villous papillomatous change in the lower rectum. *Proc R Soc Med* 61: 441-442, 1968.
- van den Boezem PB, Kruyt PM, Stommel MW, Tobon Morales R, Cuesta MA and Sietses C: Transanal single-port surgery for the resection of large polyps. *Dig Surg* 28: 412-416, 2011.
- Lim SB, Seo SI, Lee JL, Kwak JY, Jang TY, Kim CW, Yoon YS, Yu CS and Kim JC: Feasibility of transanal minimally invasive surgery for mid-rectal lesions. *Surg Endosc* 26: 3127-3132, 2012.
- Hayashi S, Takayama T, Yamagata M, Matsuda M and Masuda H: Single-incision laparoscopic surgery used to perform transanal endoscopic microsurgery (SILSTEM) for T1 rectal cancer under spinal anesthesia: Report of a case. *Surg Today* 43: 325-328, 2013.

20. Albert MR, Atallah SB, deBeche-Adams TC, Izfar S and Larach SW: Transanal minimally invasive surgery (TAMIS) for local excision of benign neoplasms and early-stage rectal cancer: Efficacy and outcomes in the first 50 patients. *Dis Colon Rectum* 56: 301-307, 2013.
21. Martin-Perez B, Andrade-Ribeiro GD, Hunter L and Atallah S: A systematic review of transanal minimally invasive surgery (TAMIS) from 2010 to 2013. *Tech Coloproctol* 18: 775-788, 2014.
22. Clancy C, Burke JP, Albert MR, O'Connell PR and Winter DC: Transanal endoscopic microsurgery versus standard transanal excision for the removal of rectal neoplasms: A systematic review and meta-analysis. *Dis Colon Rectum* 58: 254-261, 2015.
23. Rimonda R, Arezzo A, Arolfo S, Salvai A and Morino M: TransAnal minimally invasive surgery (TAMIS) with SILS port versus transanal endoscopic microsurgery (TEM): A comparative experimental study. *Surg Endosc* 27: 3762-3768, 2013.
24. Ramirez JM, Aguilera V, Arribas D and Martinez M: Transanal full-thickness excision of rectal tumours: Should the defect be sutured? A randomized controlled trial. *Colorectal Dis* 4: 51-55, 2002.
25. Hahnloser D, Cantero R, Salgado G, Dindo D, Rega D and Delrio P: Transanal minimal invasive surgery (TAMIS) for rectal lesions: Should the defect be closed? *Colorectal Dis* 17: 397-402, 2015.
26. Léonard D, Remue C and Kartheuser A: The transanal endoscopic microsurgery procedure: Standards and extended indications. *Dig Dis* 30 (Suppl 2): 85-90, 2012.
27. Bignell MB, Ramwell A, Evans JR, Dastur N and Simson JN: Complications of transanal endoscopic microsurgery (TEMS): A prospective audit. *Colorectal Dis* 12: e99-e103, 2010.
28. Simkens GA, Nienhuijs SW, Luyer MD and de Hingh IH: Massive surgical emphysema following transanal endoscopic microsurgery. *World J Gastrointest Surg* 6: 160-163, 2014.
29. Ito M, Saito N, Sugito M, Kobayashi A, Nishizawa Y and Tsunoda Y: Analysis of clinical factors associated with anal function after intersphincteric resection for very low rectal cancer. *Dis Colon Rectum* 52: 64-70, 2009.
30. Kakodkar R, Gupta S and Nundy S: Low anterior resection with total mesorectal excision for rectal cancer: Functional assessment and factors affecting outcome. *Colorectal Dis* 8: 650-656, 2006.