

# Metastatic prostate cancer initially presenting as chylothorax: A case report

YU-JIN YANG<sup>1</sup>, MINJUNG SEO<sup>2</sup>, HEE-JEONG JEON<sup>1</sup>, JIN-HEE NOH<sup>1</sup>, SEOL HOON PARK<sup>2</sup>, YUNSUOK CHOI<sup>3</sup>, JAE-CHEOL JO<sup>3</sup>, JIN HO BAEK<sup>3</sup>, SU-JIN KOH<sup>3</sup>, HAWK KIM<sup>3</sup> and YOUNG JOO MIN<sup>3</sup>

Departments of <sup>1</sup>Internal Medicine, <sup>2</sup>Nuclear Medicine and <sup>3</sup>Hematology and Oncology, Ulsan University Hospital, University of Ulsan College of Medicine, Ulsan, Republic of Korea

Received June 19, 2015; Accepted November 23, 2015

DOI: 10.3892/mco.2016.825

**Abstract.** Chylothorax is caused by disruption or obstruction of the thoracic duct, which results in leakage of chyle in the pleural space. The most common etiologies are malignancy and trauma. Among the causative malignancies, lymphoma is the most common, followed by primary lung cancer, mediastinal tumors, and other metastatic malignancies. Conversely, prostate cancer has rarely been reported as the cause of chylothorax. We herein report a case of metastatic prostate cancer initially presenting as chylothorax, with disappearance of the pleural effusion after the initiation of androgen deprivation therapy. Moreover, we also discuss the various rare manifestations of metastatic prostate cancer, including chylothorax.

## Introduction

Prostate cancer is the most common cancer among men in Western countries. The 5-year survival rate of localized and regional prostate cancer is ~100%, whereas that of metastatic prostate cancer is only 27-28% (1). As serum prostate-specific antigen (PSA) screening has become widespread, the proportion of cases presenting with lymph node involvement or advanced disease has decreased considerably (2). However, ~20% of patients present with metastatic disease. Metastatic prostate cancer usually involves the pelvic lymph nodes, bones, and lungs (2), with bone pain being a common symptom in such patients. However, there are other rare manifestations of metastatic prostate cancer. Herein, we present a rare case of prostate cancer metastasis initially presenting as chylothorax.

## Case report

A 64-year-old Asian man visited the emergency room with dyspnea. The patient's medical history was unremarkable, with the exception of being a current smoker with a 20 pack-year history. Radiographic images, including computed tomography scan of the chest, revealed a left pleural effusion, pericardial effusion, and enlarged lymph nodes in the left supraclavicular/posterior neck/axillary area, right upper paratracheal area, subcarinal area, and bilateral lower paratracheal areas (Fig. 1A and B). Thoracentesis was performed and fluid analysis revealed a chylothorax, in which the triglyceride level was 244 mg/dl (normal range, <50 mg/dl). Whole-body lymphoscintigraphy revealed faint tracer accumulation activity in the medial portion of the left hemithorax, where the pleural effusion was present (Fig. 1C). Considering that the patient had never received thoracic surgery or experienced trauma, malignancy was suspected. Pleural fluid cytology revealed numerous mononuclear leukocytes and some reactive mesothelial cells, but did not show any evidence of malignancy. The serum PSA level was elevated to 194.6 ng/ml (normal range, 0-3 ng/ml).

A prostate biopsy revealed adenocarcinoma of the prostate gland. A bone scan was performed for staging, which revealed multiple bone metastases (Fig. 1D). Therefore, the chylothorax was considered to have resulted from thoracic duct obstruction by enlarged lymph node metastasis from prostate cancer. Androgen deprivation therapy (ADT) was initiated, with simultaneous administration of goserelin and anti-androgen. After 3 months, the amount of pleural effusion had decreased (Fig. 2A) and the serum PSA level decreased from 194.6 to 31.68 ng/ml following ADT. A bone scan performed 8 months after the initiation of ADT revealed that the intensities of multiple bone uptakes had decreased significantly when compared to the initial scan (Fig. 2B). The patient is undergoing regular follow-up at our outpatient clinic for 1 year after diagnosis and has not reported experiencing any further discomfort.

## Discussion

In Korea, among males aged ≥65 years, prostate cancer is the fourth most common type of cancer and its incidence is increasing with advancing age. The crude mortality of prostate

---

*Correspondence to:* Professor Jae-Cheol Jo, Department of Hematology and Oncology, Ulsan University Hospital, University of Ulsan College of Medicine, 877 Bangeojinsunhwan-Doro, Dong-Gu, Ulsan 44033, Republic of Korea  
E-mail: jcho97@hanmail.net; jcho@uuh.ulsan.kr

**Key words:** chylothorax, metastasis, prostate cancer

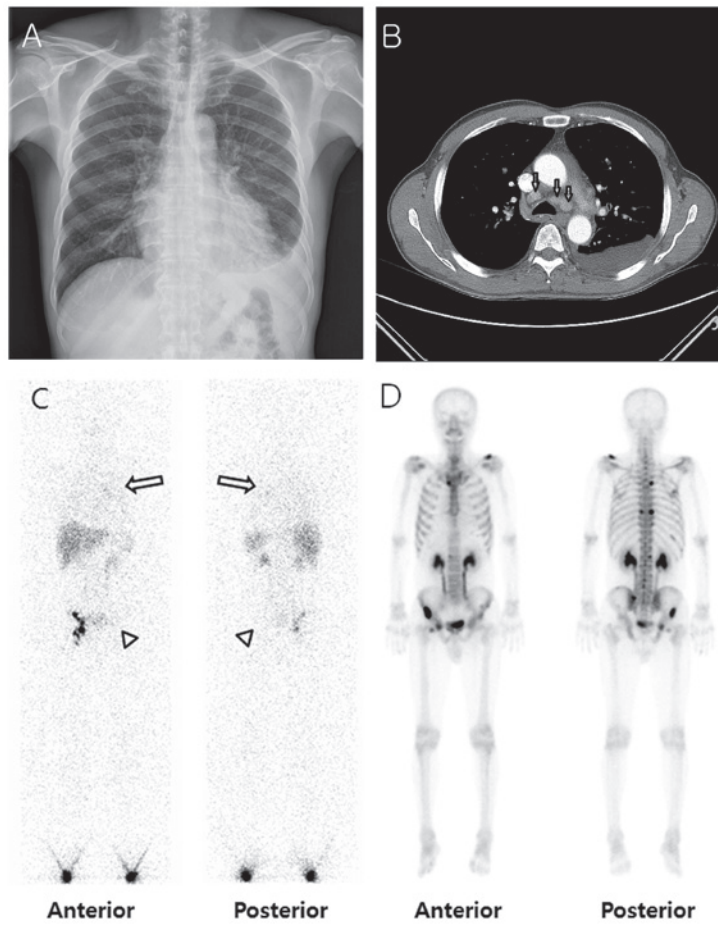


Figure 1. Chest radiography, chest computed tomography (CT), whole-body lymphoscintigraphy and bone scan images at diagnosis. (A) Chest radiography showing left pleural effusion. (B) Chest CT revealing mediastinal lymph node metastatic nodules (arrows) and left pleural effusion. (C) Whole-body lymphoscintigraphy image captured 2 h after radiotracer injection, revealing faint tracer accumulation activity in the medial portion of the left hemithorax, where pleural effusion was present (arrows). Tracer activity is absent in the left ilioinguinal chain (arrowheads). (D) Bone scan showing multiple bone metastases in the left clavicle, right ribs, thoracolumbar spine, bilateral pelvic bones and right femur.

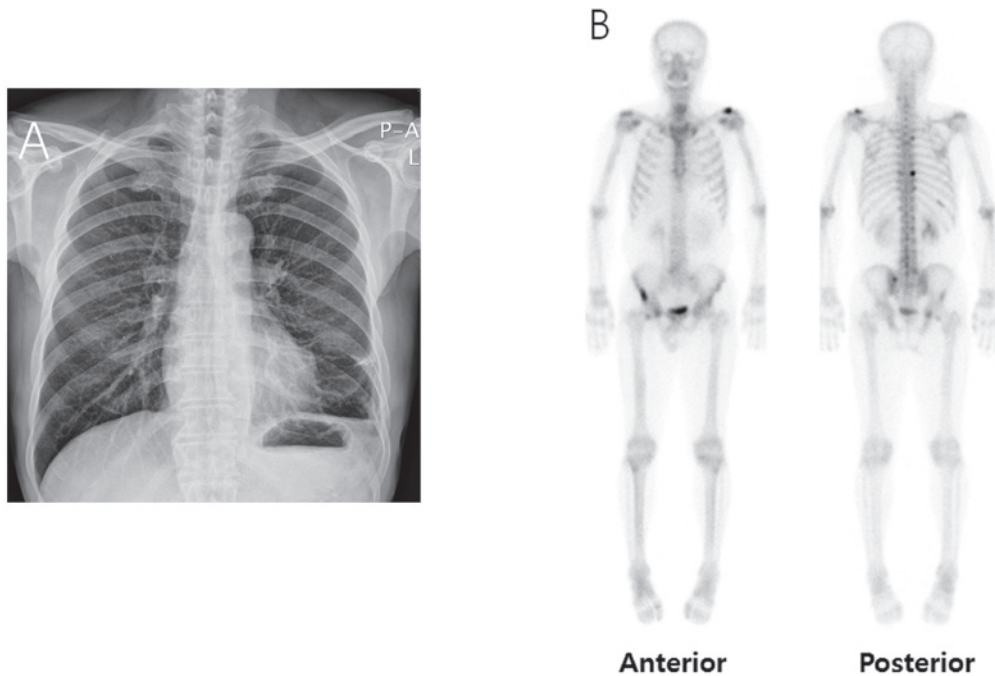


Figure 2. (A) Chest radiography and (B) bone scan at 3 and 8 months after initiation of androgen deprivation therapy, respectively. The chest radiography image shows disappearance of the previous left pleural effusion. The intensities of the multiple bone metastases are decreased on the follow-up bone scan.

Table I. Review of cases of rare manifestations from metastatic prostate cancer.

Authors	Presentation	Onset of manifestation	Age, years	Treatment	Outcome	Refs.
Mak <i>et al</i>	Skin	Late	73	Radiotherapy	Pain relief	(7)
Garai <i>et al</i>	Endobronchial mass	Initial	84	Not stated	Not stated	(8)
Ani <i>et al</i>	Ascites	Initial	57	ADT	PR	(9)
Sakata <i>et al</i>	Kidney	Late	67	Nephrectomy	PR	(10)
Ibinaiye <i>et al</i>	Kidney	Initial	55	ADT	PR	(11)
Grenader <i>et al</i>	Brain	Initial	70	Radiotherapy + ADT	PR	(12)
Rahmathulla <i>et al</i>	Brain	Initial	70	Surgical resection	PR	(13)
Patel <i>et al</i>	Pituitary gland	Late	66	Radiotherapy	PR	(14)
Kaswala <i>et al</i>	Small bowel	Late	42	Chemotherapy	Not stated	(15)
Kusaka <i>et al</i>	Testis	Late	56	Radiotherapy + ADT	PR	(16)
Mortensen <i>et al</i>	Testis	Late	89	Bilateral orchiectomy	Not stated	(17)
Tabba <i>et al</i>	Chylothorax	Late	69	Chemotherapy	PR	(18)
Quinonez <i>et al</i>	Chylothorax	Late	78	Bilateral orchiectomy + chemotherapy	PR	(19)
Present case	Chylothorax	Initial	64	ADT	PR	

ADT, androgen deprivation therapy; PR, partial response.

cancer is 2.8/10,000 and the 5-year relative survival rate by year of diagnosis from 2007-2011 was 92%, indicating that it is a highly treatable cancer (3).

There is some controversy regarding the efficacy of serum PSA screening. Randomized trials have demonstrated that serum PSA screening reduces metastatic prostate cancer incidence and disease-related mortality (4). However, other studies have reported that, due to the unnecessary biopsies following false-positive serum PSA results, cancer risk-adapted serum PSA screening is required (5). In the United States, the proportion of patients presenting with metastatic disease decreased from 17% in 1988-1990 to 4% in 1996-1998, while the proportion presenting with stage T1 tumors conversely increased from 14 to 51% (6).

As stated above, metastatic prostate cancer usually involves the pelvic lymph nodes, bones and lungs (2) and it may present as a skin lesion, endobronchial mass, ascites, or renal mass. Table I summarizes some of the rare manifestations of prostate cancer (7-19). Although our patient was not the first case of metastatic prostate cancer presenting as chylothorax, initial presentation of prostate cancer as chylothorax is quite rare (18,19).

Lymphoscintigraphy, which functionally assesses the lymphatic transport and regional lymph nodes, is an easy, non-invasive method for detecting abnormalities in the lymphatic system, including leakages such as chylothorax, chyloperitoneum and chyluria. Positive findings include tracer activity at the site where lymphatic fluid is accumulated, as seen in our case (20,21). ADT is the mainstay of treatment for patients with metastatic prostate cancer. Luteinizing hormone-releasing hormone agonists have become the standard of care in hormonal therapy, as these agents have the potential of reversibility and enable the use of intermittent androgen deprivation (22). Moreover, with ADT, patients avoid the physical and psychological discomfort associated with orchiectomy (23).

Intermittent androgen deprivation alternates androgen blockade with treatment cessation, in order to allow hormonal recovery between the treatment cycles, thus potentially improving the tolerability and quality of life. Hence, for older patients, intermittent androgen deprivation may generally be applied (24).

In summary, chylothorax is an uncommon condition. If there is no history of chest/neck injury or surgery, exclusion of malignancy is crucial. Despite its low probability, prostate cancer with mediastinal lymph node metastasis may result in chylothorax. Therefore, when we evaluate the causes of non-traumatic chylothorax, prostate cancer should be considered, and serum PSA screening is recommended to exclude this possibility.

## References

1. Siegel R, Ma J, Zou Z and Jemal A: Cancer statistics, 2014. *CA Cancer J Clin* 64: 9-29, 2014.
2. Elkin M and Mueller HP: Metastases from cancer of the prostate; Autopsy and roentgenological findings. *Cancer* 7: 1246-1248, 1954.
3. Jung KW, Won YJ, Kong HJ, Oh CM, Lee DH and Lee JS: Cancer statistics in Korea: Incidence, mortality, survival and prevalence in 2011. *Cancer Res Treat* 46: 109-123, 2014.
4. Schröder FH, Hugosson J, Roobol MJ, Tammela TL, Ciatto S, Nelen V, Kwiatkowski M, Lujan M, Lilja H, Zappa M, *et al*: Screening and prostate-cancer mortality in a randomized European study. *N Engl J Med* 360: 1320-1328, 2009.
5. Loeb S: Guideline of guidelines: Prostate cancer screening. *BJU Int* 114: 323-325, 2014.
6. Crawford ED: Epidemiology of prostate cancer. *Urology* 62 (6 Suppl 1): 3-12, 2003.
7. Mak G, Chin M, Nahar N and De Souza P: Cutaneous metastasis of prostate carcinoma treated with radiotherapy: A case presentation. *BMC Res Notes* 7: 505, 2014.
8. Garai S and Pandey U: Prostate cancer presenting as an endobronchial mass: A case report with literature review. *Int J Surg Pathol* 18: 554-556, 2010.
9. Ani I, Costaldi M and Abouassaly R: Metastatic prostate cancer with malignant ascites: A case report and literature review. *Can Urol Assoc J* 7: E248-E250, 2013.

10. Sakata R, Iwasaki A, Kobayashi M, Osaka K, Fujikawa A, Tsuchiya F and Ishizuka E: Renal metastasis from prostatic adenocarcinoma: A case report. *Acta Urologica Japonica* 57: 683-687, 2011 (In Japanese).
11. Ibinaiye PO, Mbibu H, Shehu SM, David SO and Samaila MO: Renal metastasis from prostate adenocarcinoma: A potential diagnostic pitfall. *Ann Afr Med* 11: 230-233, 2012.
12. Grenader T, Shavit L, Lossos A, Pizov G and Wygoda M: Brain metastases: A rare initial presentation of prostate cancer. *Int Urol Nephrol* 39: 537-539, 2007.
13. Rahmathulla G, Prayson RA and Weil RJ: Rare presentation of metastatic prostate adenocarcinoma as a meningioma mimic. *J Neurol Surg Rep* 75: e81-e83, 2014.
14. Patel N, Teh BS, Powell S, Lu HH, Amato R and Butler EB: Rare case of metastatic prostate adenocarcinoma to the pituitary. *Urology* 62: 352, 2003.
15. Kaswala DH, Patel N, Jadallah S and Wang W: Metastatic prostate cancer to the duodenum: A rare case. *J Family Med Prim Care* 3: 166-168, 2014.
16. Kusaka A, Koie T, Yamamoto H, Hamano I, Yoneyama T, Hashimoto Y, Ohyama C, Tobisawa Y and Yoneyama T: Testicular metastasis of prostate cancer: A case report. *Case Rep Oncol* 7: 643-647, 2014.
17. Mortensen MA, Engvad B, Geertsen L, Svolgaard N and Lund L: Metastasis in testis from prostate cancer. *Ugeskr Laeger* 176: V10130632, 2014 (In Danish).
18. Tappa M and Inaty H: A rare case of chylothorax attributed to metastatic prostate carcinoma. *J Pulmon Resp Med*: S14, 2013.
19. Quinonez A, Halabe J, Avelar F, Lifshitz A, Moreno J and Berumen AH: Chylothorax due to metastatic prostatic carcinoma. *Br J Urol* 63: 325-327, 1989.
20. Pui MH and Yueh TC: Lymphoscintigraphy in chyluria, chyloperitoneum and chylothorax. *J Nucl Med* 39: 1292-1296, 1998.
21. Prevot N, Tiffet O, Avet J Jr, Quak E, Decousus M and Dubois F: Lymphoscintigraphy and SPECT/CT using 99mTc filtered sulphur colloid in chylothorax. *Eur J Nucl Med Mol Imaging* 38: 1746, 2011.
22. McLeod DG: Hormonal therapy: Historical perspective to future directions. *Urology* 61 (2 Suppl 1): 3-7, 2003.
23. Seidenfeld J, Samson DJ, Hasselblad V, Aronson N, Albertsen PC, Bennett CL and Wilt TJ: Single-therapy androgen suppression in men with advanced prostate cancer: A systematic review and meta-analysis. *Ann Intern Med* 132: 566-577, 2000.
24. Abrahamsson PA: Potential benefits of intermittent androgen suppression therapy in the treatment of prostate cancer: A systematic review of the literature. *Eur Urol* 57: 49-59, 2010.